

Acute severe mitral regurgitation as an early complication of pacemaker implantation

Rita Miranda*, Sofia Almeida, Luís Brandão, Carlos Alvarenga, Luciano Ribeiro, Ana Rita Almeida, and Manuel Carrageta

Department of Cardiology, Hospital Garcia de Orta, Avenida Torrado da Silva, 2801-951 Almada, Portugal

*Corresponding author. Tel: +35 193 613 2273, Fax: +35 121 295 7004, Email: ritasmiranda@gmail.com

A 70-year-old man developed drug refractory acute pulmonary oedema secondary to acute severe mitral regurgitation (MR) immediately after implantation of a dual-chamber pacemaker for complete heart block. Clinical improvement occurred after allowing the patient to resume his native rhythm. A new lead was positioned within the right ventricular outflow tract (RVOT). The echocardiogram during pacing at RVOT showed minimal MR.

Case report

A 70-year-old man, referred to our hospital for asymptomatic complete atrioventricular block, underwent the implantation of a transvenous dual-chamber pacemaker. Two passive fixation leads were positioned, respectively, at the right ventricular apex and right atrial appendage.

Immediately after implantation, the patient developed drug refractory acute pulmonary oedema. He underwent urgent Doppler echocardiographic examination that demonstrated preserved ventricular function, normal left atrial size, no organic mitral leaflet disease, and severe MR due to incomplete coaptation of mitral leaflets (*Figure 1A and B*).

The pacemaker was then reprogrammed to VVI at 30 bpm, minimizing pacing and allowing patient to resume his native rhythm. There was an immediate improvement in the patient's symptoms.

The hypothesis of acute severe MR secondary to ventricular dyssynchrony induced by right ventricular apical (RVA) pacing was suspected in this patient.

It was decided to extract the ventricular lead, and a new active fixation ventricular lead was positioned within the RVOT (*Figure 2*). The echocardiogram after this last procedure and during ventricular pacing showed normal mitral leaflet coaptation and minimal mitral

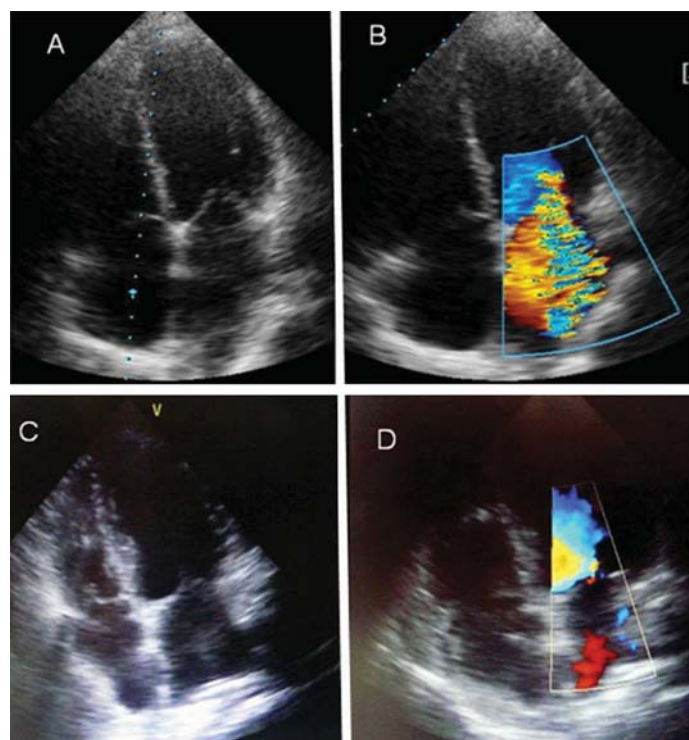


Figure 1 Two-dimensional echocardiogram with colour Doppler flow in the apical four-chamber view showing severe MR during right ventricular apical pacing (*A and B*) and demonstrating minimal mitral regurgitation during RVOT pacing (*C and D*).

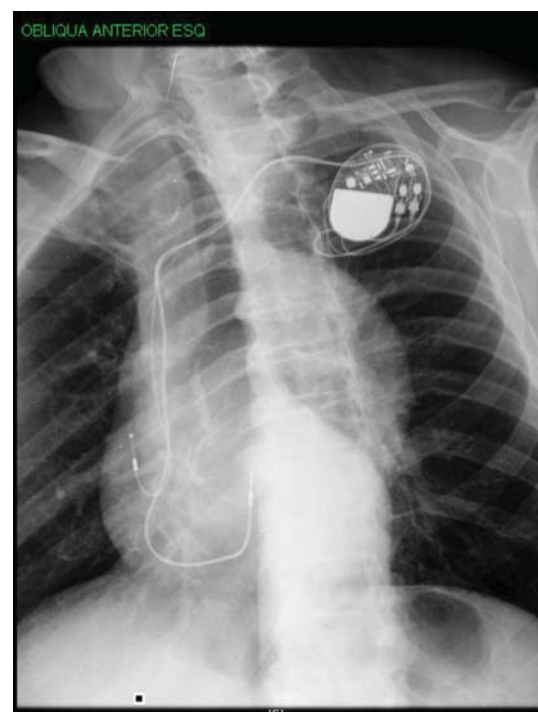


Figure 2 Left anterior oblique chest radiograph showing the position of the ventricular lead within the RVOT.

regurgitation (Figure 1C and D). The patient remained haemodynamically stable and made an uneventful recovery from the episode, remaining asymptomatic at follow-up.

Discussion

RVA pacing produces a number of unfavourable effects due to an abnormal left ventricular electrical-activation sequence, namely functional MR caused by left ventricular dyssynchrony and alterations in the timing of papillary muscle contractions.¹

Most cases of pacemaker-induced, functional MR and congestive heart failure are described several months after pacemaker implantation, like in the article by de Guillebon *et al.*² There are few reported cases of acute severe MR as an immediate perioperative complication of permanent pacemaker insertion, leading to acute haemodynamic deterioration.³

Our case report demonstrates that RVA pacing may immediately induce severe MR and acute cardiac failure, even in patients with preserved left ventricular contraction. This case shows the clinical and echocardiographic improvement of acute mitral regurgitation induced by RVA pacing by RVOT pacing, probably by improving ventricular dyssynchrony,⁴ obviating the need of a more complex procedure for upgrading to a biventricular device in a patient with no previous symptoms of heart failure and with preserved left ventricular function.

This shows the importance of the preservation of a normal ventricular activation sequence, a critical determinant of normal mitral valve function, during permanent cardiac pacing¹ even in patients with normal left ventricular function.

Conflict of interest: none declared.

References

1. Sassone B, De Simone N, Parlangeli R, Tortorici G, Biancoli S, Di Pasquale G. Pacemaker-induced mitral regurgitation: prominent role of abnormal ventricular activation sequence versus altered atrioventricular synchrony. *Ital Heart J* 2001;**2**:441–8.
2. de Guillebon M, Bordachar P, Clementy J. Regression of mitral regurgitation after cardiac resynchronization therapy in an adult with preserved left ventricular function and right ventricular pacing. *Europace* 2007;**9**:768–9.
3. Haider A, Banerjee S, Brilakis ES. Acute pulmonary edema due to pacemaker-induced mitral regurgitation. *J Invasive Cardiol* 2008;**20**:E84.
4. de Cock CC, Giudici MC, Twisk JW. Comparison of the haemodynamic effects of right ventricular outflow-tract pacing with right ventricular apex pacing. A quantitative review. *Europace* 2003;**5**:275–8.